

# Focus on Stones

**Professor Tan Arulampalam *MD FRCS***

Consultant Surgeon, Colchester Hospital

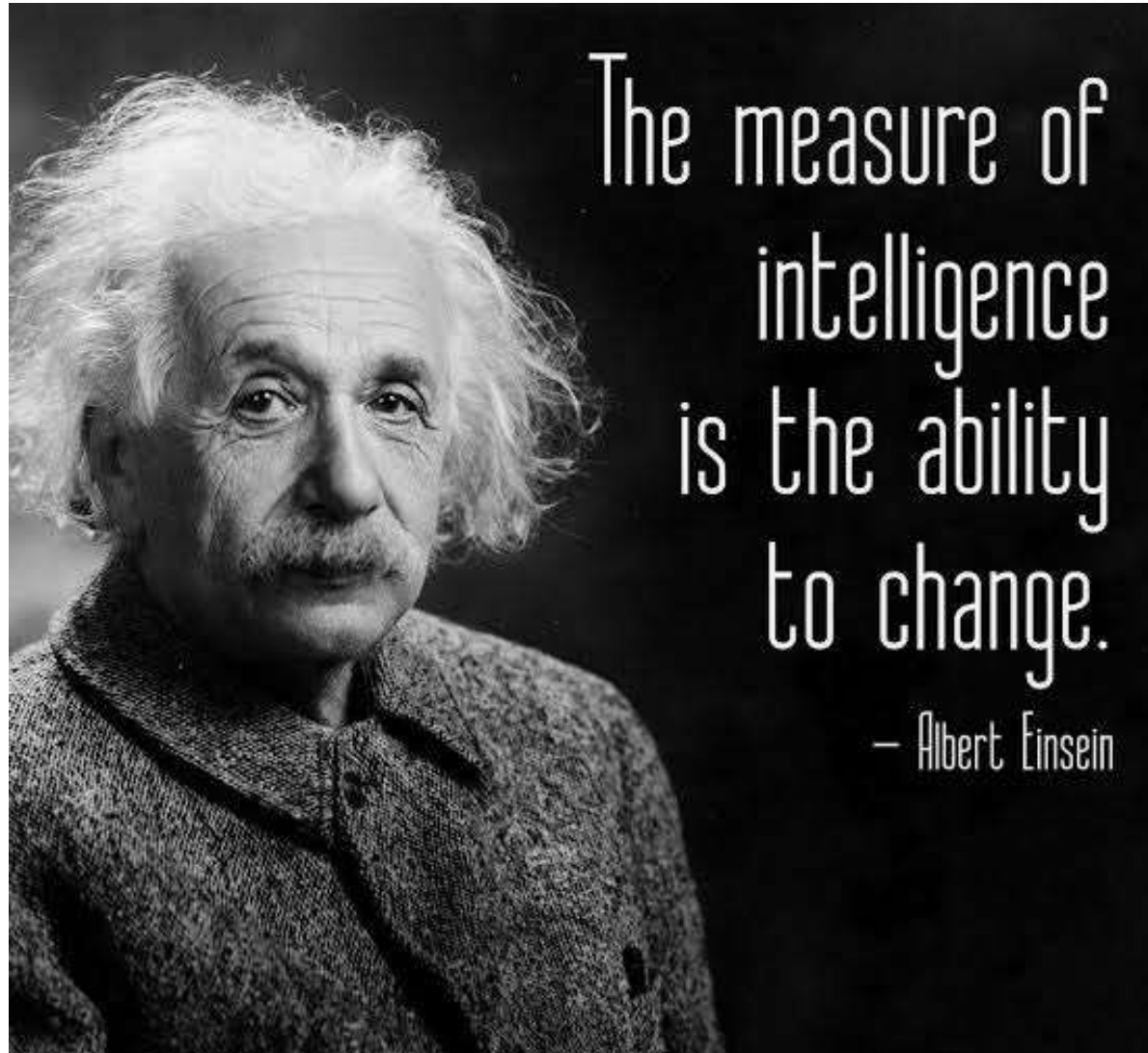
Professor of Surgery, School of Medicine

Anglia Ruskin University

@Laptan1



# Its NOT about the Stones



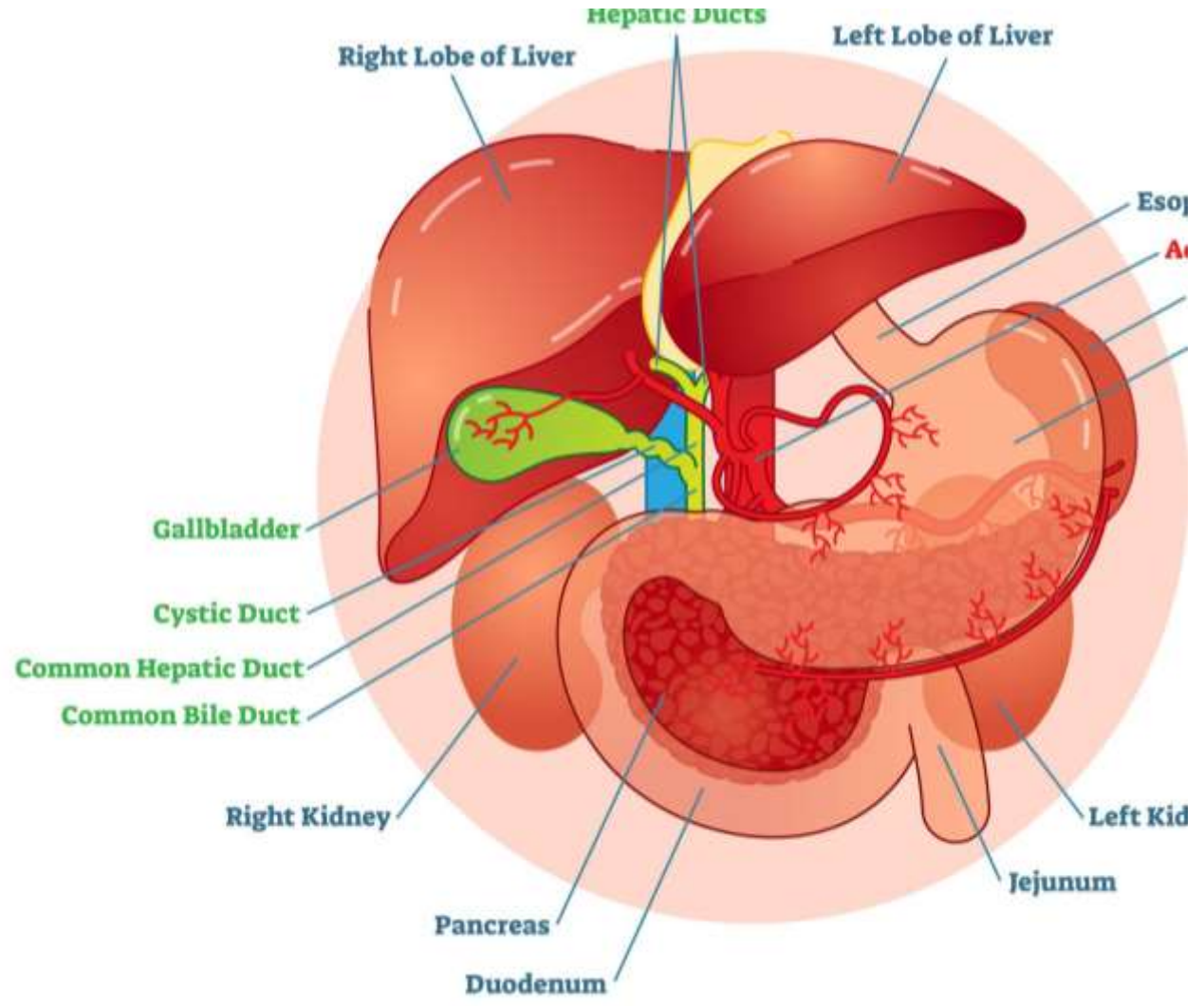
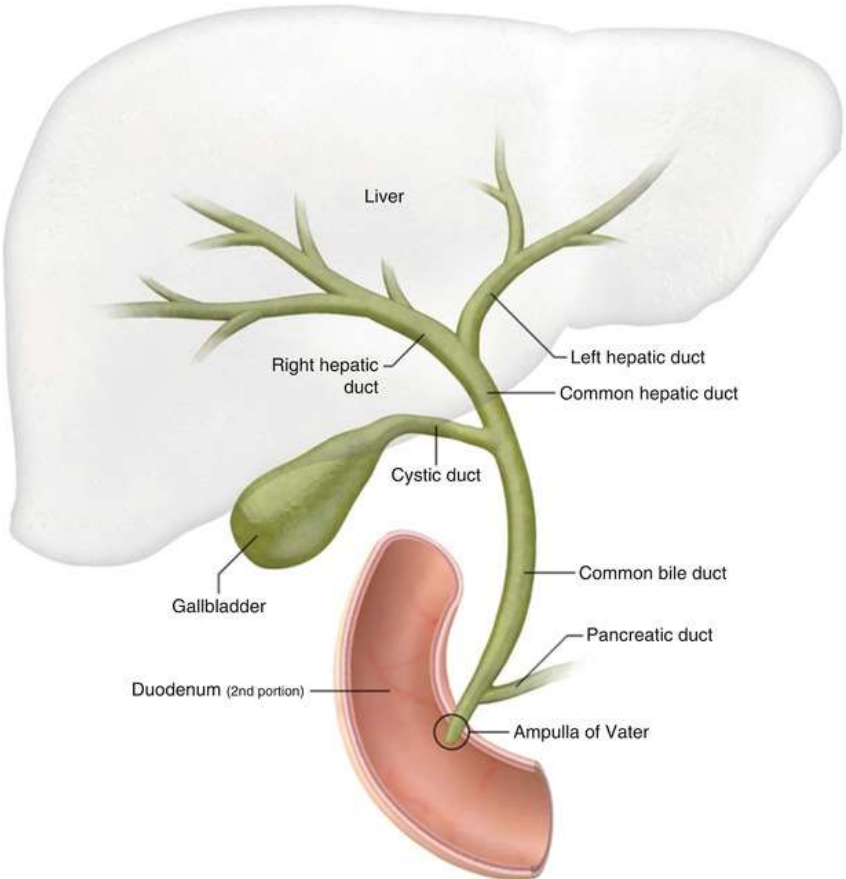
# The Plan: Learning objectives

- Explore symptom complexes
- Quality of the pain
- What about Age
- Investigations
- Post operative Complications

Pause your video please:

Can you sketch the biliary tree?

# Anatomy



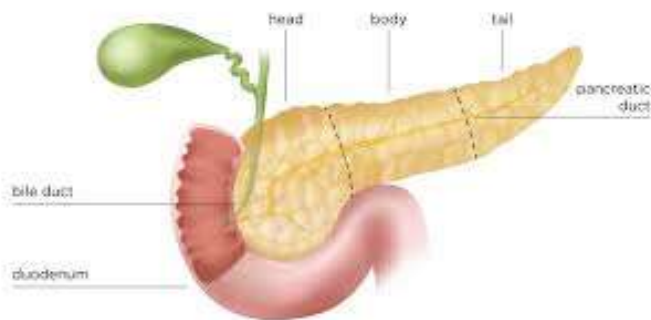
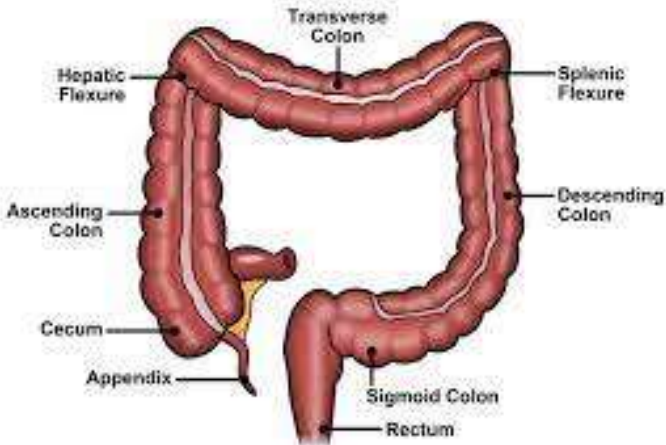
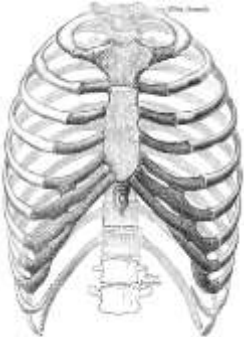
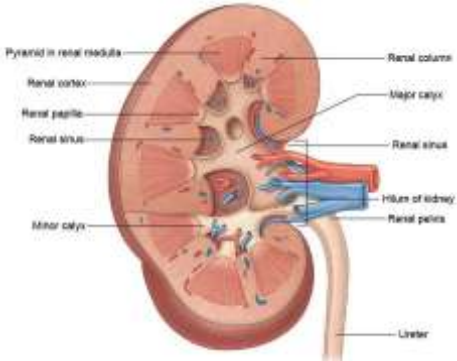
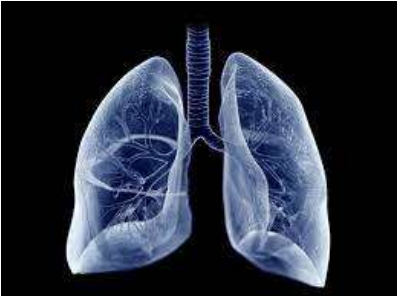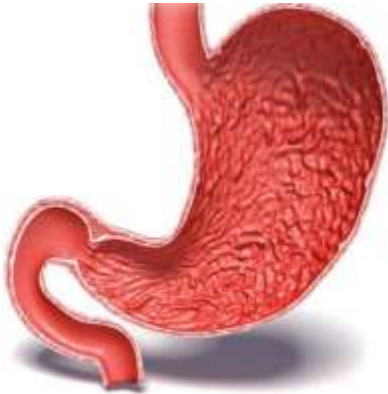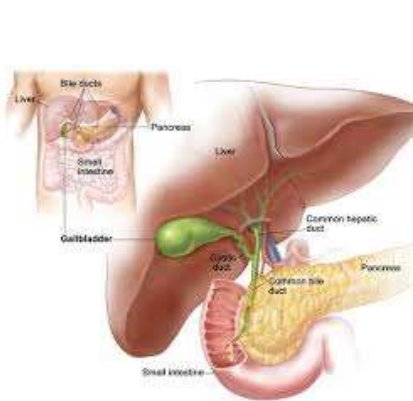
# Why

- Cholecystitis
- Biliary pain
- Pancreatitis
- GB polyps
- Abnormality on CT

Pause your video please:

What is your differential diagnosis for  
right upper quadrant/ upper abdominal pain?

# Differential Diagnosis





# Symptom Bubbles

Pain after eating

Radiation to shoulders/back

Off food

Bloating

Change in bowel habit

Bloating

Jaundice

Weight loss

Anaemia

Thrombocytosis

Cachexia

Tender costal cartilage

Pause your video please:

Key features of pain?

# What is your Pain like?

Band like pain  
After eating  
Radiation

Indigestion  
?reflux pain

Rolling around or lying still

Loin pain

Point tenderness

# Age

- 20-40
- >40
- >70

# Investigation

Haematology  
Biochemistry

USS: Gallstones  
Wall thickness  
CBD calibre  
Anything else

CXR

OGD

# Management

Emergency:

Cholecystitis

?inpatient or community

Jaundice

Refer urgently

Pancreatitis

urgent admission

Biliary pain

pain relief, bowel rest  
or ?admission

USS for diagnosis

2WW for upper or lower GI cancer

Elective:

Biliary pain

Lap Cholecystectomy

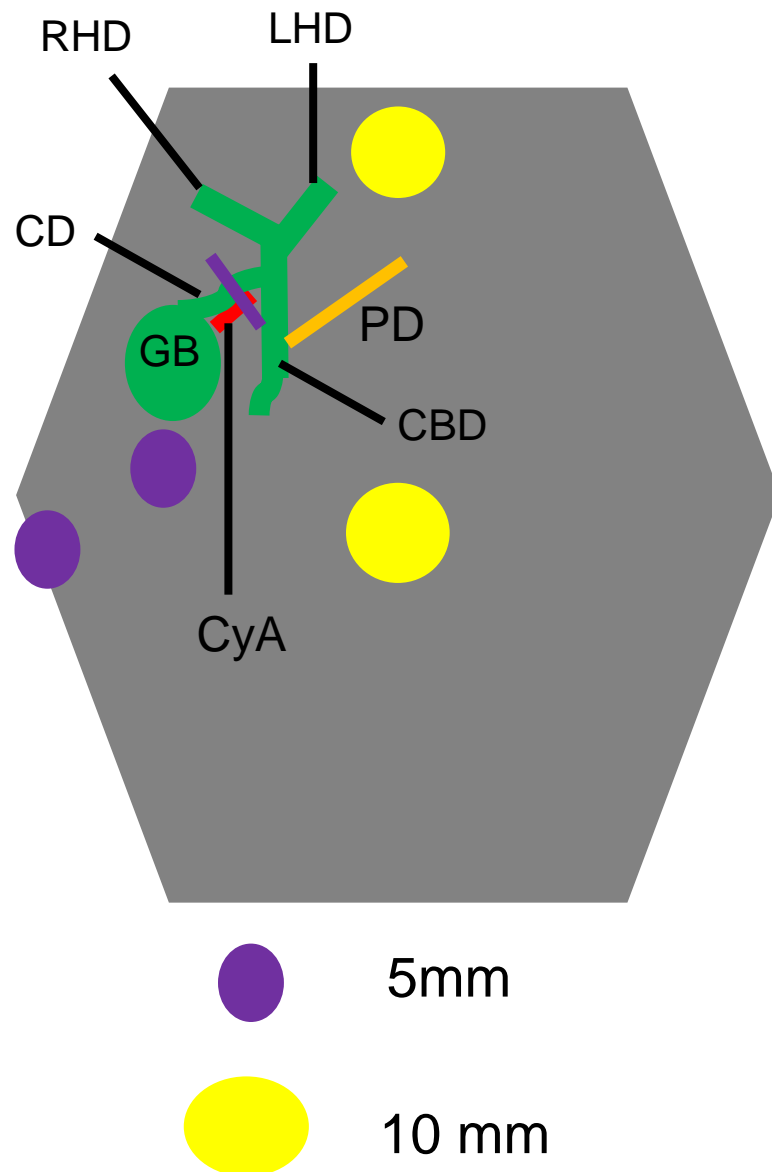
Dyspepsia

PPI  
Exclude HP and Cancer

GORD

Lifestyle  
?manometry

## How



- Central camera (10mm 30 degree)
- Identify the pathology and laparoscopy
- Retract the Gallbladder fundus
- Dissect cystic duct (Calot's Triangle)
- Intraoperative Cholangiogram
- Clip and divide the cystic duct then artery
- Dissect GB off it's fossa
- Extraction in a bag
- ?Washout
- Checks

Pause your video please:

What are the common presentations in primary care after laparoscopic cholecystectomy?



# Complications

- General Complications
- Collection
- Biliary duct damage
- Wound infection
- Bleeding
- Urinary
- Hernia
- VTE
- Change in bowel habit

# Key Message:

Does this patient have gallstone disease

Quality of symptoms

Ultrasound

Post operative complications require urgent attention